Fellow American Academy
of Forensic Sciences

Nizam Peerwani, MD, D-ABFP
Senior Forensic Consultant
Board Certified in Anatomic, Clinical and Forensic Pathology
P.O. Box 121634, Arlington, Texas 76012
Phone: 817-966-1739 Fax 817-496-9641

September 14, 2019

Mr. Eyal Sagiv
Data Coordinator, B'Tselem
The Israeli Information Center for Human Rights in the Occupied Territories
P.O. Box 53132
Jerusalem 9153002, Israel

Dear Mr. Sagiv,

Re: 'Abd a-Raahman a-Shteiwi

I have received from you several documents pertaining to the head shot sustained by 'Abd a-Raahman a-Shteiwi in the village of Kafr Qaddum on July 12, 2019, including:

1. Two media publications which provide summary of events leading to the gunshot wound sustained by 'Abd a-Raahman a-Shteiwi (henceforth "Abed a-Shteiwi").
2. CT scan from Rafidia hospital in Nablus
3. CT scan from Edmond and Lily Safra Children's Hospital in Tel Aviv.
4. A video taken of the CT done on Rafidia hospital.
5. Photographs:
    a. General scene photos where the incident occurred.
    b. Two photographs of Abed a-Shteiwi.
    c. Bullets and casings found at the scene.
6. Medical records from Rafidia Hospital.
7. Medical records Edmond and Lily Safra Children's Hospital in Tel Aviv.

I am a medical doctor, licensed to practice medicine in the State of Texas, and I specialize in forensic pathology. I am board certified in anatomic, clinical and forensic pathology and I serve as the Chief Medical Examiner for the counties of Tarrant, Parker, Denton and Johnson in the State of Texas. Over the past forty years, I have performed several thousands of forensic examinations many of which involved injuries caused by firearms including those due to high velocity weapons such as 5.56-mm (.223 caliber) and 7.76-mm. I have previously investigated killings in Srebrenica, Rwanda, Guatemala, Occupied West Bank and Gaza (2nd Intifada and Jenin Refugee Camp), Iraq and Afghanistan. I have also investigated injuries caused by high velocity weapons and rubber bullets deployed by Israeli Defense Forces during the 2nd Intifada in West Bank

and Gaza, and in Jenin.

In this case, you have asked me to review the information you have provided and to render an opinion regarding the gunshot wound sustained by Abed a-Shteiwi. You have specifically requested that I render opinion based on best evidence whether the pattern of injury exhibited by Abed a-Shteiwi is due to deployment of a rubber bullet or a high velocity weapon by the soldiers from the Israeli Defense Forces (IDF).

As mentioned in an earlier publication[1] during the 2014 invasion of Gaza, a group of physicians serving in Gaza published an editorial letter in *The Lancet*, describing "the massacre in Gaza," which they claimed spared no one, including the disabled and sick in hospitals, children playing on the beach or on the roof top, along with wanton destruction of hospitals, clinics, ambulances, mosques, schools, and thousands of private homes. Whilst these observations may have been accurate, this group of physicians serving in war-torn Gaza were not just investigators—they were humanitarians advocating cessation of hostility. It is not the intention of this assessment to be an advocate.

However, in forensics, opinions rendered pertaining to mechanism of injury and injury patterns are based on underlying circumstances. Hence, brief discussion in this report regarding the social and political environment, including weekly demonstrations and suppression response by IDF in the township of Kafr Qaddum that culminated in Abed a-Shteiwi sustaining a near-fatal gunshot wound of the head are pertinent and should not be construed as advocacy.

Background

Kafr Qaddum is a Palestinian town in the occupied northern West Bank, located 13 kilometers west of Nablus and 17 kilometers east of Qalqilya in the Qalqilya Governorate. Most of the 4,000 residents are from the extended Shteiwi family.

Photo-1: Kafr Qaddum

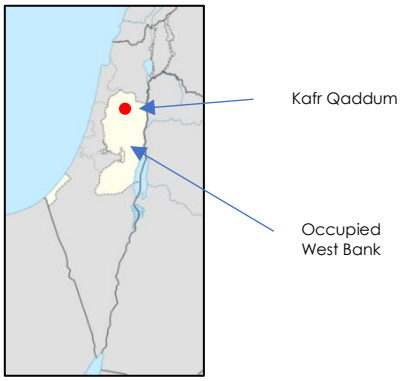

Map-1: Kafr Qaddum

[1] Peerwani, N. The Role of a Forensic Pathologist in Armed Conflict. Acad Forensic Pathol. 2017 Sep;7(3):370-389.

Kafr Qaddum is only a few hundred meters from Kedumim, the nearest Israeli settlement ffounded in 1975 by members of the Gush Emunim settlement movement. Kedumim now has a population exceeding 4,500. The main road from Kafr Qaddum to the city of Nablus was closed by Israel during the second Palestinian intifada (uprising). The closure coincided with the expansion of the illegal Israeli settlement of Kedumim in 2003. Israel claims it closed the road for security reasons.

Since July 2011, weekly demonstrations have been held in a demand to re-open the road. But also, to protest other grievances. Kafr Qaddum has been subjected to numerous Israeli confiscations for the benefit of the various Israeli objectives, including the construction of Israeli settlements, outposts, and bypass roads on the village territories. This is in addition to the Segregation Plan realized through the Segregation Wall. Furthermore, the inhabitants of the town experience acute water shortages, especially in summer months, so that the settlements receive adequately water supply.

There are also allegations reported by the media that IDF have suppressed protests using various other tactics, including "attack dogs", "collective punishment", night-time arrest raids, and use of putrid "skunk water" These allegations made by the media have not been independently verified.

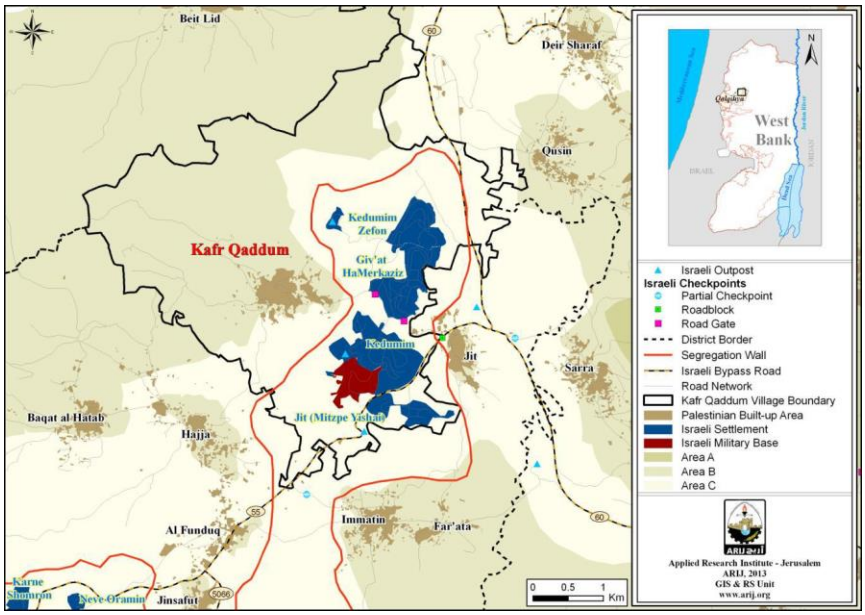

Map-2: Israeli Settlement and Kafr Qaddum

The road closure has imposed significant hardships. Addameer[2] claims that the "..the only alternative road is roughly six times longer than the previous route, disrupting the villagers' ability to attend university, jobs, and other vital aspects of their economic and social wellbeing." Road closures have also cut off the residents from their farming lands.

Demonstrations in Kafr Qaddum are typically held on Fridays after the noon prayers. The demonstrators burn tires and throw stones at soldiers, who use tear gas, rubber bullets (see below) and from time-to-time live ammunition to disperse the demonstrators.

[2] Addameer is a Palestinian NGO established as Prisoner Support and Human Rights Association that works to support Palestinian political prisoners held in Israeli and Palestinian prisons.

Incident Summary

Abed a-Shteiwi was 9-years of age when he sustained a gunshot wound to his head. According to eye witnesses he was playing at the entrance of a house by the roadside in the village of Kafr Qaddum when around 2:00 PM on Friday, 12 July 2019, soldiers from the IDF fired live round which struck Abed in the head. Abed fell to the ground. Residents transported Abed by Red Crescent ambulance to Rafidia Hospital in Nablus where he was observed to be unconsciousness on arrival. He underwent neurosurgical intervention and then on 13 July 2919, he was transferred to ICU at Chaim Sheba Medical Center in Tel Aviv for higher care.

Eye Witness Testimony

Witness statements were obtained by 'Abd al-Kareim a-Saad'di, B'Tselem Field Representative.
Date and Place: Not Specified
Eye witnesses wished to remain anonymous.

Eye Witness	Location of Victim	Range	COMMENT
N.S.	In front of a house in the shade of an olive tree	100 m	Witnessed one soldier on the ridge of Mount al'Aqra'a firing 4 – 5 rounds towards 8 – 10 guys in the village near the water tower. He then aimed his rifle and fired one bullet directly to the place where the victim was found striking him in the head. The boy fell to the ground with lots of blood coming down his head.
No Personal Details	He observed 3 – 4kids under an olive tree next to the road opposite his house	100 m	Around 14:20 pm, one shot came from the mountain ridge where the soldiers were located. He then observed one kid falling to the ground. A neighbor evacuated the body to a nearby ambulance.
A.S.	Did not observe – but later visited the site and observed blood and parts of human flesh.	450 m	After the guys had burnt the tires, a group of soldiers arrived and started firing rubber bullets. Later the soldiers started shooting "live fire" bullets in the air in massive quantities. The clashes lasted for one hour without injuries. When the procession was about to end and the guys were returning to the homes, he heard someone say that a child was injured in the head. He observed a guy carrying the wounded boy to the ambulance.

M.S.	Sitting along the road side under an olive tree	100 m	At 14:30 PM, the weekly march was nearing an end because the military forces shot massive fire, much more than usual. As he walked on the same road that 3 – 4 boys were, he heard firing and simultaneously screaming. Before he arrived, he observed other guys pick up the victim and carry him a Red Crescent ambulance. The shots came from the mountain ridge.
R.S.	Outside a house under an olive tree	100 m	He was under an olive tree with his twins watching the demonstration near the water tower. He observed 4 – 5 soldiers soldier on the ridge of Mount al'Aqra'a with one soldier sitting in a military position on his knees and aiming his rifle at them. He took his twins and walked toward the victim who was standing outside a house. When he was 2 meters away from the victim, the soldier fired one round which struck the victim in the head. He picked up the victim and ran towards the ambulance.
Twins K and M	Twins K and M were children of eye-witness "R.S". Their account is omitted.		

Hospital Records

A. Medical Report from Rafidia Hospital, Nablus (Occupied West Bank)[3]

Clinical Summary

Date/Time of Admission: July 12, 2019 at 15:26 PM
Date/Time Discharged: July 13, 2019 at 13:43 PM

Admit History: Abed a- a-Shteiwi was unconscious and covered with blood. The report indicated that the entrance wound was along the right frontal area with a corresponding exit along the left occipital region. He was obtunded, non-responsive, exhibited severe hypoxemia and had lost significant amount of blood

Laboratory findings revealed:
pH: 7.387 (N = 7.35 – 7.345)
pCO_2: 43.2 mmHg N = 32 – 48)
pO_2: 62.9 mmHg (N = 83 – 100)
Hematocrit: 22.2% (N = 36 – 53)

[3] Rafidia Surgical Hospital is a government hospital in the Nablus city, Occupied West Bank, Palestine under the authority of Palestinian Ministry of Health. It was built in 1976 and has 200 surgical beds.

Hemoglobin: 8.10 g/dL (N = 11.5 – 17.8)
Glucose: 110 mg/dL (N = 63 – 95)
Electrolytes: Within normal range
CT-scan: "Multiple fragments of exploded bullet spreading all over the brain tissue mainly in the right frontal lobe and causing injury to the cerebral arteries."

Hospital Course: Abed a- a-Shteiwi received emergent decompressive craniotomy with ventriculostomy and insertion of a shunt. Post-op, he remained unconscious with pupils constricted but reactive. The surgery was performed by head of neurosurgery department, Dr. Othman Othman. It was elected to transfer him to Edmond and Lily Safra Children's Hospital at Chaim Sheba Medical Center in Tel Aviv for higher care.

Media Reporting: Dr. Othman talking to the media claimed a live round was used: "He [Abed a- a-Shteiwi] had a penetrating injury in the frontal lobe on the right side. The injury was severe and there are more than 100 fragments. This is not a rubber bullet; this is a metal bullet. A rubber bullet will not enter because it does not have a sharp head. This is something that had a sharp head." He further opined that "I have seen many gunshot wounds and they only break into a few pieces. Over 100 fragments is not normal." (This information cannot be verified)[4]

(Note: Review of CT scans from Rafidia Hospital as well as Edmond and Lily Safra Children's Hospital at Chaim Sheba Medical Center provided by B'Tselem show only an entry gunshot wound. An exit wound was not observed. Furthermore, Mr. Eyal Sagiv, Data Coordinator for B'Tselem orally reported that Dr. Othman from Rafidia Hospital had verbally stated to him that there was an error in the report and that no exit wound was present. It appears that this error was carried over to Edmond and Lily Safra Children's Hospital at Chaim Sheba Medical Center in Tel Aviv which also stated that there was an exit wound).

B. The Edmond and Lily Safra Children's Hospital[5] in Tel Aviv

Clinal Summary

Received a 9 years and 10 months old with healthy background, and vaccinated for his age for advance care from Rafidia Hospital in Nablus. The patient had sustained gunshot wound on 13.7.19 with traumatic brain injury. He was operated in Nablus where a ventriculostomy was inserted. He was transferred to Chaim Sheba Medical Center in

---

[4] July 15, 2019 at 12:43 pm | Published in: International Organisations, International Solidarity Movement (ISM), Israel, Middle East, News, Palestine.
https://www.middleeastmonitor.com/20190715-over-100-bullet-fragments-in-brain-of-palestinian-child-shot-by-israel-soldier/

[5] Completed in 2002 the Edmond and Lily Safra Children's Hospital includes a state-of-the-art intensive care unit, an inpatient hematological unit that performs bone marrow transplants and intensive chemotherapy, pediatric surgical department that serves all of the pediatric subspecialties including neurosurgery, cardiac surgery, orthopedics, and urology, and Congenital Heart Center.

Tel Aviv to ICU for higher care. During hospitalization, the ventriculostomy was removed. Culture grew Acinetobacter. He remained unconscious and exhibited a Glasgow Coma Scale (GCS) of 6, breathing independently with tachypnea, tachycardia and fevers up to 39° C. Also, there was suspicious of clinical seizure.

Vitals:

Temperature	38.3 P.A
Pulse	122/minute
Blood pressure	116/74 mm Hg
Number of breaths	25/minute

Treatment: Piperacillin (antibiotic), Ofloxacin (antibiotic), Duratears (ophthalmic ointment) Tramadol (narcotic-like pain reliever), Phenytoin (anti-seizure), Clonidine (anti-hypertensive), Keppra (anti-seizure), Propranolol (beta blocker), Klaxon (non-steroidal anti-inflammatory.

CT Scan: CT revealed air in the upper part of the brain tissue that is exposed from the skull bones secondary to the craniotomy (previous) as well as multiple staple clips in scalp. Skull revealed fracture with shift of parietal bone on the left as well as fractures of the roof of the right eye socket and in the socket's medial wall. Multiple cerebral hemorrhages including subdural hemorrhage along the plexus and the tentorium bilateral, the paramedian brain tissue on the right around the numerous shrapnel fragments and intraventricular hemorrhage in right frontal horn, in the occipital and temporal horns bilateral, as well as in the third and fourth ventricles were observed. There was associated widespread edema in the cerebral tissue surrounding the hemorrhages. Additionally, there were multiple shrapnel fragments in the cerebral parenchyma projecting multiple artifacts, mostly right of the midline were noted.

Assessment of CT-Scans and Head Trauma

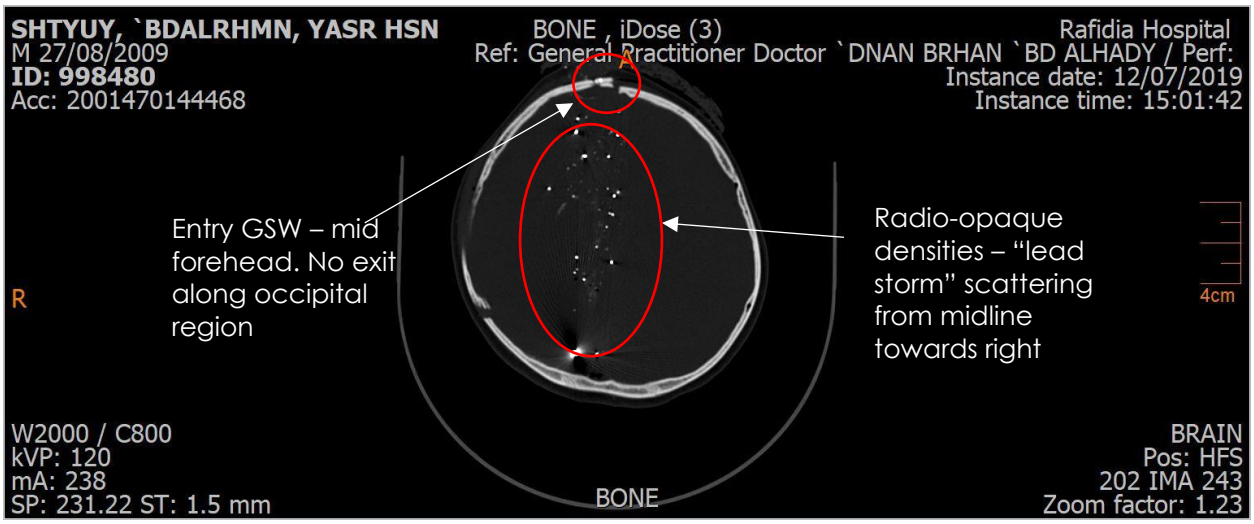

CT-1: CT-scan obtained at Rafidia Hospital, Nablus on 07-12-2019

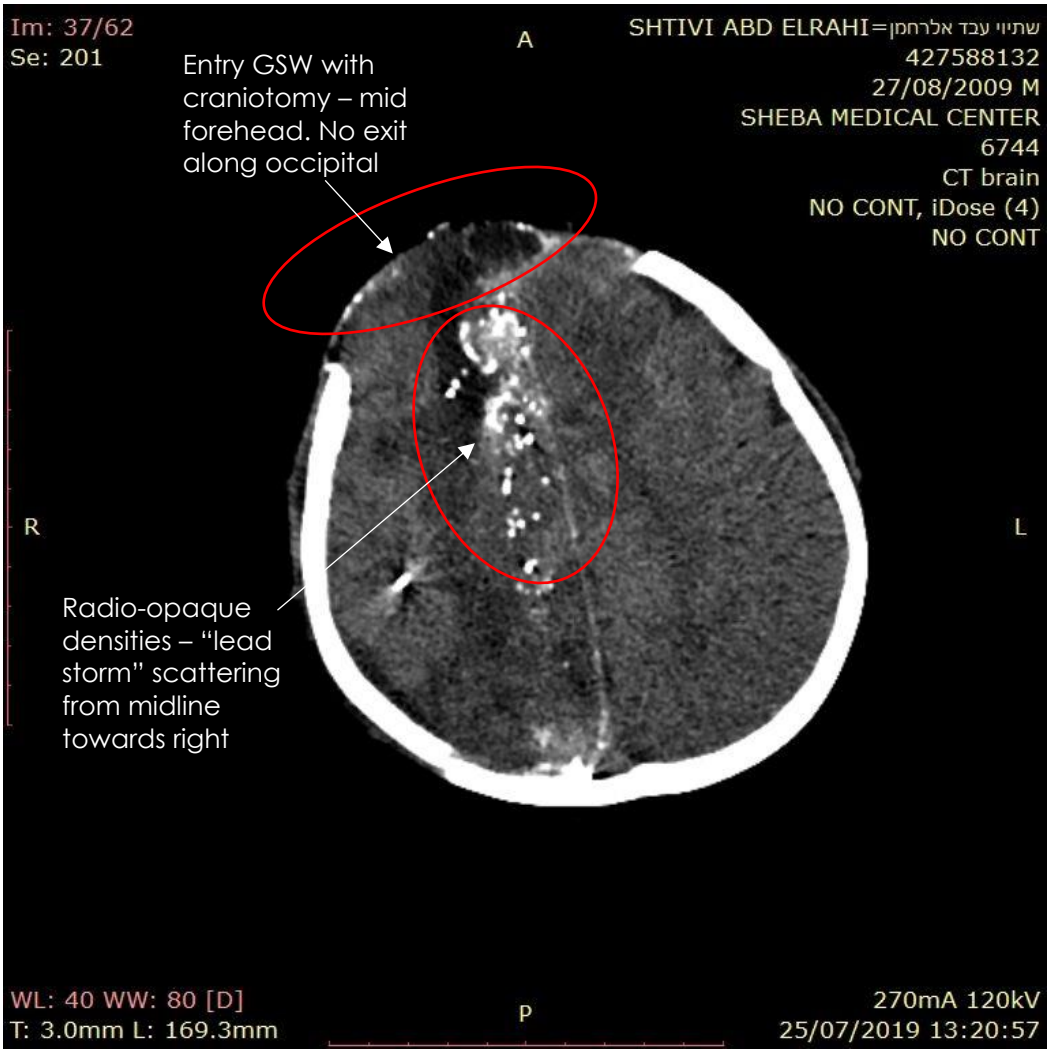

CT-2: CT-scan obtained at Edmond and Lily Safra Children's Hospital on 07-25-2019

Conclusion: I concur with the reported CT-scan findings from Rafidia Hospital and Edmond and Lily Children's Hospital. The entry is located more towards the midline with the bullet following a trajectory into the right hemisphere. There is, however, no exit gunshot wound. The large number of radio-opaque densities observed in both the CT-scans are consistent with "lead storm" typically observed in high velocity firearm injuries such as those caused by .223-cal (5.56-mm). Rubber bullets with steel core are not known to produce lead storms (see below – discussion under Rubber Bullets).

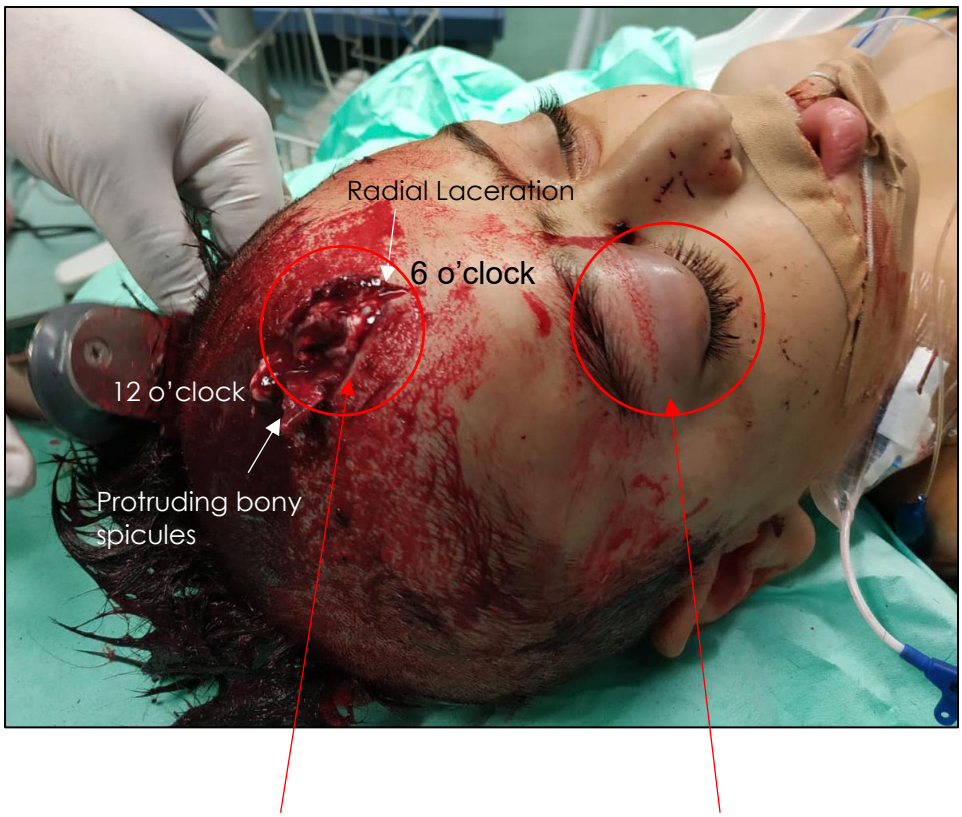

Photo-2: Photograph of Abed a-Shteiwi at Rafidia Hospital
Source: B'Tselem

Conclusion: Abed a-Shteiwi sustained a gunshot wound of mid-forehead. The wound reveals absence of soot deposition, powder tattooing or a muzzle imprint and is consistent with an entry gunshot wound fired from a distant range. There is a radial laceration at 6 o'clock and evidence of protruding bony spicules at 12 o'clock. There are no irregular marginal abrasions which would indicate yaw and or tumbling of the bullet which are frequently present with entry wounds produced by a rubber bullet fired at a range exceeding 40 meters (< 40 m is considered as safe range). Although there is fracture of the right orbit, this is not due to ocular penetration. Rubber bullets have a low muzzle velocity, 70 meters/sec (200 feet/sec) with a kinetic energy of 400 J. Hence, their penetration through the skull is unusual unless they strike the ocular area. Additionally, the lead storm observed in the CT-scans is highly unusual for rubber bullets. In summary, the wounding patterns observed are all consistent with injury produced by a high velocity gunshot wound.

Discussion

A. High Velocity Weapon

The damage caused by a projectile striking a body occurs by two different mechanisms. The first is laceration and crushing which is the sole method by which low-velocity handguns cause damage to tissues. Higher velocity weapons will stretch the tissue in the wake of the bullet, forming what is called a temporary cavity as well as the accompanying smaller permanent cavity. The temporary cavity is created by stretching forces in a vacuum in the wake of a bullet, and the volume of this cavity is proportional to the energy which is transferred, with a maximum diameter being measured at 10 to 40 times the bullet diameter. This temporary cavity will actually collapse and reform repeatedly with a diminishing amplitude until it settles down to what will be the permanent cavity. This entire process only lasts one to five milliseconds. At autopsy, an examiner usually observes the permanent cavity.

A bullet with muzzle velocity of 2000 feet/sec (610 m/sec) or greater is considered as high velocity (US definition). The temporary and permanent cavities produced by such a bullet striking the soft tissue is illustrated in the Diagram-1 below.

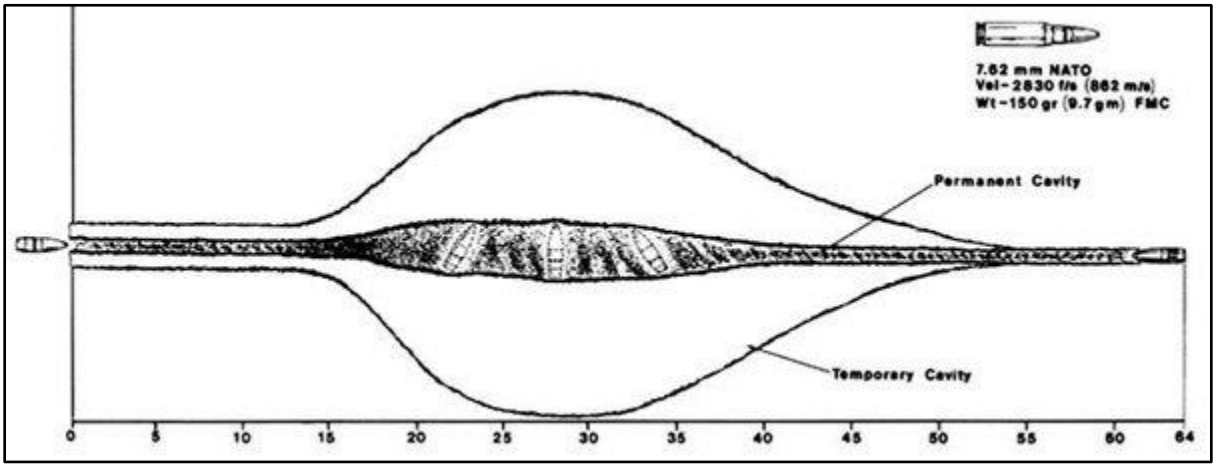

Diagram-1: Permanent and Temporary Cavities.
High Velocity gunshot track: Impact speed > 2000 feet/sec

High velocity wounds tend to cause more substantial tissue damage and are caused by military and hunting weapons. The severity of wounding is not just based on the velocity of the bullet. The projectile's mass and striking velocity only determine the potential for tissue disruption. The true tissue damage is due to actual energy transfer to the tissue. The efficiency of energy transfer is affected by various factors some of which include:

a. Range of fire: The farther the projectile is away from the target, the lower the velocity at impact, and hence the lower the kinetic energy it will contain.
b. Stability of projectile and how it strikes the body surface. Position of the center of gravity of the bullet also determines whether the bullet in its forward trajectory will yaw or not. When the center of gravity is off-center, a bullet is more likely to yaw. Additionally, bullets fired from a short barrel impart greater yaw for a short distance after leaving the muzzle.
   The greater the yaw a bullet possesses when it strikes its target, greater is the likelihood of the bullet fragmenting.
c. Caliber, construction, configuration, and shape of the projectile are also very important in affecting energy transfer. Full metal jacket bullet will tend not to deform once it strikes tissue and may pass through the target without imparting much of its kinetic energy. In contrast, soft point bullet will flatten out or mushroom or fragment on impact.
d. The biological characteristics of tissues are important when affecting energy transfer of the bullet. Unlike more elastic tissue such as, skeletal muscle and lower-density elastic tissue such as lung, tissues with near-water-density, less elastic tissue including brain, liver, or spleen and fluid-filled organs including the heart, bladder, or gastrointestinal tract, are damaged more severely by a large temporary cavity.

B. Rubber Bullet

Plastic or rubber bullets have been used extensively by both the British and Israeli authorities in riot control. They are intended to incapacitate by inflicting painful and superficial injuries without killing or inflicting serious bodily harm when fired at ranges no less than 30 to 70 m depending on the missiles with fire directed at the lower extremities. Rubber bullets are rubber or rubber-coated projectiles that are fired from riot guns. They were developed by the British in 1970 for use against people in Northern Ireland. A low power propelling charge gave them a muzzle velocity of about 70 meters/sec (200 feet/sec), kinetic energy of 400 J. and maximum range of about 100 meters (110 yards). The intended use is to fire at the ground so that the round bounces up and hits the target on the legs, causing pain but not injury.

As in metal bullets, the wounding potential of a rubber bullet is established to a large extent by the efficiency with which its kinetic energy is transferred to tissue on impact. The kinetic energy of a missile is defined as the mass of the missile multiplied by the square of its velocity. Velocity of the missile on impact determines the severity of injury, since doubling the velocity quadruples the kinetic energy, whilst doubling the mass only doubles the kinetic energy. An important factor in velocity of impact is the missile's ballistic coefficient, which is an expression of its ability to overcome air resistance. The ballistic coefficient is a function of mass, shape, and diameter of the projectile.

Rubber bullets are made so that low kinetic energy is imparted to the victim at the so-called safe range of 40 m when aimed at the lower limbs. This low ballistic coefficient,

however, results in:

1. Unstable flight of the missile, which tends to yaw and tumble end-over-end. This is easily discerned on body surface at the point of enrty where there are irregular abrasions surrounding the entrance defect indicating that the bullet had struck the skin sideways.

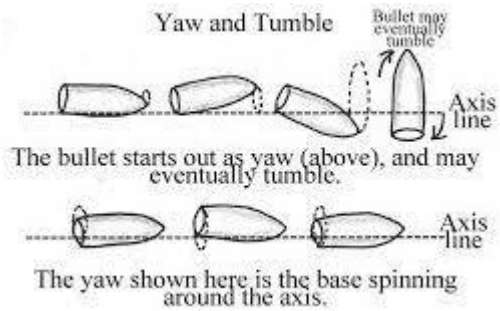

2. Inaccurate erratic flight, which makes it difficult or sometimes impossible to avoid hitting the face, head, and upper torso.

Published data however do describe injuries caused by rubber bullets. Millar[6] and colleague reported injuries in 90 patients caused by rubber bullets. In their series, there was 1 death with 17 people suffering permanent disabilities or deformities. They concluded that although the mortality rate was very low, just one in 16 000 fired rounds in Northern Ireland, serious injury was much higher with a ratio of one in 800 and a disability ratio of one in 1900. Similar reports have been published by Khonasari[7], Suyama[8] and Khobayshi[9]. While Dhar SA et sl[10] as well as Charlier et al[11] have argued whether projectile-based riot control method can ever be truly non-lethal and should these weapons be re-classified as lethal.

Mahajna et al[12] published a detailed report in 2002 describing blunt and penetrating injuries caused by rubber bullets during the Israeli-Arab conflict in October 2000. Israeli rubber bullets are produced in two main types. The older type, the standard rubber bullet, is a steel sphere coated in a thin layer of rubber, weighing 14 grams, while the

---

[6] *Millar, I..* "Injuries caused by rubber bullets: A report on 90 patients". *British Journal of Surgery. 62 (6): 480–486*

[7] Khonasari, RH et al., Severe facial rubber bullet injuries: Less lethal but extremely harmful weapons, Injury, 41, 1, (73-76), (2010).

[8] Suyama, J et al. Injury patterns related to use of less-lethal weapons during a period of civil unrest, The Journal of Emergency Medicine, 25, 2, (219-227), (2003).

[9] Kobayashi M. et al. Rubber Bullet Injury, The American Journal of Forensic Medicine and Pathology, 30, 3, (262-267), (2009).

[10] Dhar, S.A. et al. Can a projectile-based riot control method ever be truly non-lethal?, Journal of the Royal Army Medical Corps. 163, 2, (152-152), (2017).

[11] Charlier, P. et al. Unusual Death by Rubber Bullet. Should These Guns Be Reclassified as Lethal Weapons? Amer J. Foren Med and Path. 2012. 33: pe4.

[12] Mahajna, A. et al. Blunt and penetrating injuries caused by rubber bullets during the: a retrospective study, The Lancet, 359, 9320, (1795-1800), (2002).

newly improved rubber bullet, introduced in 1989, is a rubber-coated metal cylinder 1.7 cm in diameter, weighing 15.4 grams.[13]

Photo – 3 and 4: Rubber bullets

Mahajna reported 595 casualties admitted to the hospital during Israeli-Arabs riots in early October 2000 (2nd Intifada). Of these, a total of 152 patients with proven injuries caused by rubber bullets were studied retrospectively, including 151 males and one female (age range 11-59 years). Injuries described were distributed randomly over the body surface and were mostly located in the limbs (n=73), head, neck, and face (61), chest (39), back (16), and abdomen. Over 60% patients sustained merely blunt injuries, whereas in 40%of cases, the rubber bullets had penetrated the bodies. There were a total of just three casualties, two due to penetrating ocular injury into the brain one as a result of postoperative aspiration after a knee injury.

In summary, rubber bullets are more likely to cause blunt trauma and when they penetrate the body tissues are generally not associated with mortality, unless the traumatic brain injury is from an ocular injury. Furthermore, in none of these cases did the rubber bullet fragment on impact causing "lead storm" as observed in the CT-scan of Abed a-Shteiwi.

[13] The rubber-coated bullets deployed during 2nd Intifada also included 1.83-cm steel core w/3-mm rubber coating fired from a metallic canister by M-16 observed by this investigator in occupied West Bank and Gaza in October 2000.

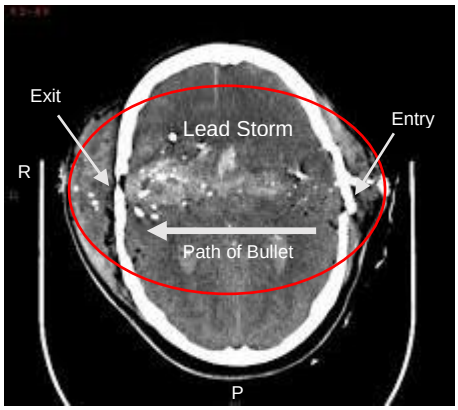

CT Scan – 3: GSW of head with **high velocity weapon**. Entry and exit gunshot wounds with prominent lead storm (multiple radio-opaque fragments in the brain and right parietal subgaleal). Patient was died
Source: Bickle, I and Macri F. et al. https://radiopaedia.org/articles/high-velocity-penetrating-brain-injury?lang=us

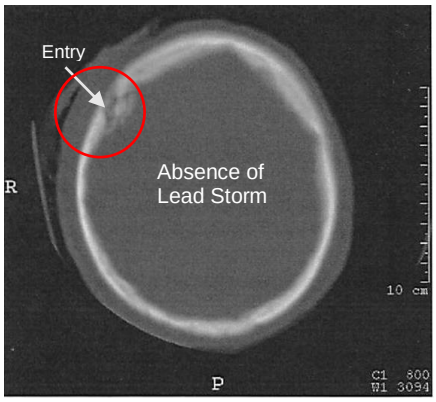

CT Scan – 4: GSW of head with **rubber bullet**. Bullet caused open fracture of right parietal bone with subarachnoid hemorrhage. No penetration into brain. No lead storm. Patient was discharged after 2 days.
Source: The Lancet. 359:1798 (2002)

CT Scan – 5: GSW of head sustained by Abed a-Shteiwi with prominent lead storm
Source: Edmond and Lily Safra Children's Hospital on 07-25-2019

More recently, in well-publicized media reports, nine protesters, including a Norwegian activist and a Palestinian child, were shot and injured by Israeli forces by rubber bullets during the weekly settlement march in the Kafr Qaddum. The Norwegian activist, Kristen Foss, a volunteer with the International Solidarity Movement, sustained a shot in the abdomen on 18 August 2018 and again in the ankle less than a week later while joining the protest march, by two rubber-coated steel bullets. These incidences once again demonstrate that the rubber-coated steel bullets have a low propensity to cause fatal or near-fatal injuries.

Opinion

The pattern of traumatic brain injury observed in the wounding of ‘Abd a-Raahman a-Shteiwi by Israeli Defense Forces is consistent with deployment of a high velocity weapon. It is very unlikely that a rubber bullet would cause the injury observed.

Yours sincerely,

Nizam Peerwani, MD, D-ABFP
Senior Forensic Consultant